

## TWO CASES OF PREMATURE SUTURE CLOSURE AMONG THE ANCIENT INHABITANTS OF ANATOLIA

MUZAFFER SÜLEYMAN ŞENYÜREK, Ph. D.

*Professor of Anthropology, University of Ankara*

In an earlier study on the longevity of the ancient Anatolians<sup>1</sup>, I pointed out the presence of two skulls showing premature suture closure among the ancient inhabitants of Anatolia. These two skulls which had been only briefly referred to in this previous paper are dealt with in the present study. One of these skulls is from Kaledoruğu near Samsun (Kaledoruğu No. I) and the other is from Alaca Höyük in Çorum (Alaca Höyük No. 9).

### KALEDORUĞU No. I

This skeleton was found in the Copper Age stratum of Kaledoruğu, near Samsun in northern Anatolia, excavated by Drs. Kılıç Kökten, Nimet Özgüç and Tahsin Özgüç<sup>2</sup> and is now preserved in the Department of Anthropology of the University of Ankara. This skull is represented by a calva, a broken maxilla and a mandible. In the calva most of os frontale, the greatest portion of parietals, the largest part of the right and a part of the left temporal bones have been preserved. In addition to these, the greatest portion of the squamous part of the occipital bone is retained intact. The right maxilla and a part of the left maxilla are also preserved, but as the medial part of the latter is broken and missing, the maxilla has not been restored. The mandible is well-preserved, only the right coronoid process being damaged.

<sup>1</sup> Şenyürek, M. S. : A note on the duration of life of the ancient inhabitants of Anatolia. The American Journal of Physical Anthropology, vol. 5, N. S. No. 1, 1947, p. 56.

<sup>2</sup> Kökten, K., Özgüç, N. and Özgüç, T. : 1940 ve 1941 yılında Türk Tarih Kurumu adına yapılan Samsun bölgesi kazıları hakkında ilk kısa rapor. Belleten, vol. IX, No. 35, 1945, pp. 361—400. In this report the length and breadth measurements and the cranial indices of only the skulls of adults are given.

*The Age and Sex :*

All the deciduous teeth of this child had erupted and had been used. Of the permanent set, only the first upper and lower permanent molars had erupted, but the roots of these are still incomplete<sup>3</sup>. Therefore this skull belongs to a child of approximately 7 years of age.

As the skull is that of a child it is difficult to determine the sex with certainty. In an earlier study<sup>4</sup> I had published the measurements of the teeth of a mixed series consisting of Europeans, ancient Egyptians, Negroes, Melanesians and American Indians, which I had measured at the Peabody Museum of Harvard University. The comparison of the first permanent molars of this child with the measurements of the corresponding teeth of this mixed series shows that the teeth are very small indeed. Although nothing definite can be said about the sex of this child, the small size of the first permanent molars suggests that it is a girl.

*The Condition of the Sutures :*

The pars bregmatica and the pars verticis of the sagittal suture are completely closed on both the endocranial and ectocranial aspects of the skull (Fig. 1). In the pars obelica and pars postica regions of this suture lamina externa of the bone is damaged, but a part of lamina interna is preserved on the endocranial surface together with some of the diploë. Pars obelica and pars postica have been closed on the endocranial aspect of the skull, and the condition of the diploë suggests that these parts may also have been closed ectocranially. The pars bregmatica of the coronal suture is synostosed on both the ectocranial and endocranial surfaces (Fig. 1). The pars complicata of the coronal suture is partially synostosed on the ectocranial surface of the skull, but most of it is closed on the inner side. On the other hand, the pars temporalis of the coronal suture is still open on both the external and internal surfaces of the calva.

<sup>3</sup> See Şenyürek, M. S. : Anadolunun eski sakinlerinde taurodontism. (The occurrence of taurodontism in the ancient inhabitants of Anatolia). Belleten, vol. XIII, No. 50, 1949. Pl. XXVIII, Fig. 1.

<sup>4</sup> Şenyürek, M. S. : Türk Tarih Kurumu adına yapılan Maşat Höyük kazısından çıkarılan kafataslarının tetkiki (Study of the skulls from Maşat Höyük, excavated under the auspices of the Turkish Historical Society). Belleten, vol. X, No. 38, 1946. Table 2.

The lambdoid suture is also patent on both the ectocranial and endocranial surfaces. The sphenoparietal, sphenotemporal, squamous and parietomastoid sutures are also completely open on both the outside and inside. Unfortunately the region of the occipitomastoid suture is broken, so it has not been possible to determine the condition of this suture, which has been found to show the highest frequency of premature closure according to the findings of Bolk<sup>5</sup> and Lenhossek<sup>6</sup>. Thus it is seen that in Kaledoruğu No. I the sagittal suture and parts of the coronal suture have already been obliterated at the age of 7. The stage of synostosis of the sagittal suture and of pars bregmatica and pars complicata of the coronal suture of this skull show a condition normally attained at about the 35th—38th year<sup>7</sup> of life in whites. That is, the sagittal suture and parts of the coronal suture of this child were closed about 30 years before the normal time.

*Other features of the calva :*

This calva is dolichocephalic, hypsicephalic and akrocranic (Tables 1 and 2). The measurements of this calva are compared below (Table 1) with those of other children :

<sup>5</sup> Quoted by : Poirier, P. - Charpy, A. (A. Nicolas, editor) : *Traité d'anatomie humaine*, vol. 1, Paris, 1931, pp. 572—573 ; Ashley-Montagu, M. F. : *Anthropometry. Aging of the skull*. American Journal of Physical Anthropology, vol. XXIII, No. 3, 1938, p. 368.

<sup>6</sup> Quoted by Ashley-Montagu : *op. cit.*, 1938, pp. 368—369.

<sup>7</sup> 35th and 38th years are the times of complete synostosis of respectively the sagittal suture and of pars bregmatica and pars complicata of the coronal suture on the endocranial surface of the skull of whites, according to the findings of Todd and Lyon. See Todd, T. W. and Lyon, D. W.: *Endocranial suture closure. Its progress and age relationship. Part I - Adult males of white stock*. American Journal of Physical Anthropology, vol. VII, No. 3, 1924, pp. 325—384.

TABLE I.

	Length	Breadth	Porion- Bregma Height	Mean Thickness of Parietal	Cranial Index	Po-b- Length Index	Po-b- Breadth Index
Kaledoruğu No. 1 (7 years old)	153.50	112.00	107.00?	2.30	72.96	69.70?	95.53?
A Copper Age child from Alaca Höyük (one year old or somewhat younger) <sup>8</sup>	160.00?	120.00	—	—	75.00?	—	—
Skull of an Aust- ralian aboriginal child (from Keith, 1931, p. 89) <sup>9</sup>	162.00	117.00	102.00 <sup>10</sup>	—	72.22 <sup>11</sup>	62.96 <sup>11</sup>	87.17 <sup>11</sup>
A protohistoric Anatolian child from Alaca Höyük (3-4 years old) <sup>12</sup>	169.00	122.00	96.50	2.60	72.18	57.10	79.09
A brachycephalic recent Anatolian child (No. 1396) (About 6 years old)	153.00	123.00	102.00	2.42	80.39	66.66	82.92

<sup>8</sup> See Şenyürek, M. S. : A note on the human skeletons in the Alaca Höyük Museum. Ankara Üniversitesi Dil ve Tarih-Coğrafya Fakültesi Dergisi (Université d'Ankara, Revue de la Faculté de Langue, d'Histoire et de Géographie), vol. IX, No. 1-2, 1951. (In the press).

<sup>9</sup> This Australian aboriginal child is of about the same age as Kaledoruğu No. I, as Keith states that "*the first permanent molar had just erupted*," (Keith, Sir. A. : New discoveries relating to the antiquity of man. London, 1931, p. 88).

<sup>10</sup> Auricular height.

<sup>11</sup> Calculated from Keith, 1931.

<sup>12</sup> This Alaca Höyük skull is preserved in a box at Alaca Höyük Museum, together with the bones of a new born, or at the most a few months old, infant. Although the accompanying note says that these bones are from the place where the "Hittite iron," was found, I have not yet been able to learn whether the bones of these two individuals were found together and from precisely what level or levels they are derived. See Şenyürek : op. cit., 1951.

From this table it is seen that Kaledoruğu No. I skull differs from the longheaded children listed in having a smaller length and breadth. It agrees with the brachycephalic child in length, but differs from it in having a smaller width. In height Kaledoruğu No. I exceeds all the other skulls. The mean thickness of the parietal, measured about one centimeter above the squamous suture, is somewhat less than in the other specimens even though the others having this measurement are younger. Kaledoruğu No. I does not differ much from some of the longheaded skulls in the cranial index, but differs from all the listed skulls, including the roundheaded specimen, in having greater height-length and height-breadth indices<sup>13</sup>. In short the Kaledoruğu specimen differs from the longheaded children listed, of the same age or even younger, in having a smaller length and breadth, a thinner parietal bone and a greater height.

The form of the skull of this child is ovoid (Fig. 1). The forehead is vertical and the glabella and brow ridges have not yet developed. The metopic suture is completely synostosed and along its course is seen a pronounced sagittal elevation (sagittal crest). The frontal eminences are of moderate development, while the parietal eminences are weak. The temporal fullness is of medium development. A sagittal elevation of medium degree is observed in the parietal region. On both sides, just above and behind the external auditory meatus there exists a foramen of moderate size. The glenoid fossa is still of submedium depth. In norma lateralis the occiput is well-curved and protuberant. There is no plano-occipital flattening in the occiput (Fig. 2).

There is no wormian fossa in the occipital bone. In the cerebral surface of the calva, the juga cerebralia and the digitate impressions on the frontal and parietal bones are very pronounced, being more

<sup>13</sup> Ehrich (Ehrich, R. W. : Preliminary notes on Tarsus crania. American Journal of Archaeology, vol. XLIV, No. 1, 1940, p. 89) gives the length, breadth and the auricular heights of some children's skulls (mostly between 7—12 years of age, except No. 11 which is 13—17 years old) from the "early cemetery," at Tarsus. These skulls exceed Kaledoruğu No. I in length, breadth and mean thickness of the parietal. Kaledoruğu No. I exceeds Tarsus Nos. 11 and 14 in absolute height, but is surpassed by No. 13 whose auricular height is 116.5 mm. However, in both height-length and height-breadth indices Kaledoruğu No. I exceeds all the skulls from the Chalcolithic early cemetery at Tarsus, including No. 13.

marked on the left than on the right side. The juga cerebralia and the digitate impressions of this calva are much more pronounced than those of the normal children with which I have compared it.

The sutura infraorbitalis is still patent on the right and left sides, in both the facial surface of the maxilla and in the floor of the orbit. On the palatal aspect of the right maxilla, a trace of the sutura incisiva is still preserved. The mandibular measurements are listed in Table 3. The chin, which is pointed, shows only a very slight projection (Fig. 3). The symphysis rises almost vertically, as is usually the case in children. The uppermost part of the symphysis is still patent. On the left side the mental foramen is single and is situated below the first milk molar. On the right side, the mental foramen is below the distal root of the first milk molar. On the anterior margin of the right mental foramen there is seen a second but tiny orifice. There are several very minute pores in the symphysis region of the mandible.

The measurements of the preserved deciduous teeth are listed in Tables 4 and 5. The milk teeth not listed in these tables have all been lost after death. The measurements of the permanent first upper and lower molars are given in Tables 6 and 7. The first permanent upper molar, on both sides, possesses four well-developed cusps. The hypocone of this tooth is well-developed. The chewing surface of the crown is slightly wrinkled. On the mesiolingual corner of the protocone there exists a Carabelli pit<sup>14</sup>. The first permanent lower molar, of both the right and left sides, has five cusps; the mesoconid (hypoconulid) being well-developed. This tooth shows Milo Hellman's<sup>15</sup> plus-pattern. The chewing surface is coarsely wrinkled.

The milk molars are noticeably worn, with some large islands of dentine exposed, while in the first permanent upper and lower molars only the enamel has been abraded and no dentine is exposed.

<sup>14</sup> For Carabelli pit see : Gorjanovic-Kramberger : Die Kronen und Wurzeln der Mahlzähne des Homo primigenius und ihre genetische Bedeutung. Anatomischer Anzeiger, vol. 31, 1907, p. 120. ; Weidenreich, F. The dentition of *Sinanthropus pekinensis* : A comparative odontography of the hominids. Palaeontologia Sinica, New Series D, No. 1 (Whole Series No. 101), Peiping, 1937, p. 75.

<sup>15</sup> Hellman, M. : Racial characters in human dentition. Proceedings of the American Philosophical Society, vol. 67, No. 2, 1928, pp. 157--174.

The first right lower milk molar is preserved in situ, but the first left lower milk molar is found isolated. This first left lower molar shows a large carie on the distal part of the crown, and its distal root is damaged near the middle of its lingual side. The socket of this tooth is extensively absorbed. So it appears that this tooth was badly abscessed, being held in its extensively absorbed alveolus mostly by the soft parts, thus easily coming off its socket after death. The other preserved teeth have no caries.

As it is a child that is being dealt with here, it is difficult to say whether it belongs to the Eurafican or to the Mediterranean racial type, which are the two longheaded elements present among the Chalcolithic and Copper Age populations of Anatolia, the majority of which were dolichocephalic<sup>16</sup>. I will leave this as an open question. Kaledoruğu skull differs from the normal longheaded children of comparable or even younger age, with which it has been compared, mainly in having some sutures prematurely closed and in its smaller cranial length and breadth. This child shows a tendency in the direction of microcephaly.

#### ALACA HÖYÜK No. 9

This skeleton was found in the Copper Age stratum of Alaca Höyük in 1936, and is believed to have been caught and killed under the falling stones during an earthquake<sup>17</sup>. The calva of this skeleton

<sup>16</sup> See Şenyürek, M. S. : (a) Anadolu Bakır Çağı ve Eti seknesinin kraniyolojik tetkiki (A craniological study of the Copper Age and Hittite populations of Anatolia). Belleten, vol. V, No. 19, 1941 ; (b) Şenyürek, M. S. : Truva civarında Kumtepe'de bulunmuş olan iskeletlere dair bir not (A note on the skeletons from Kumtepe in the vicinity of Troy). Ankara Üniversitesi Dil ve Tarih-Coğrafya Fakültesi Dergisi (Université d'Ankara, Revue de la Faculté de Langue, d'Histoire et de Géographie), vol. VII, No. 2, 1949 ; (c) Şenyürek, M. S. : Büyük Güllücek'de bulunan Kalkolitik çağa ait bir muharibin iskeletinin tetkiki (Study of the skeleton of a Chalcolithic Age warrior from Büyük Güllücek). Ankara Üniversitesi Dil ve Tarih-Coğrafya Fakültesi Dergisi (Université d'Ankara, Revue de la Faculté de Langue, d'Histoire et de Géographie), vol. VIII, No. 3, 1950 ; (d) Şenyürek: op. cit., 1951.

<sup>17</sup> See Koşay, H. Z. : Türk Tarih Kurumu tarafından yapılan Alaca Höyük hafriyatı. 1936 daki çalışmalara ve keşiflere ait ilk rapor. Türk Tarih Kurumu yayınlarından, Series V - No. 2, Ankara, 1938, p. 69.

has already been studied by me<sup>18</sup> and by Kansu and Tunakan<sup>19</sup>, who have also added the maxillary and mandibular measurements to the list<sup>20</sup>. In my study of 1941<sup>21</sup> dealing only with the calva and calvarium measurements of the ancient Anatolians, the measurements of this calva were given as averages with those of Alaca Höyük skull No. VII<sup>22</sup>. Kansu and Tunakan's measurements for this and No. VII<sup>23</sup>, listed separately, agree exactly with mine<sup>24</sup>. As I have now been able to restore the forehead more fully by finding a piece missing from the side of the frontal bone, I have added the minimum frontal diameter to the list of measurements. I have also remeasured the maxilla and the mandible; the measurements of which are listed respectively in Tables 9 and 10.

*The Age and Sex :*

In this individual all the permanent molars have erupted with the exception of the upper and lower wisdom teeth. As for the epiphyses of the long bones, in the preserved lower half of the right humerus the lower epiphysis is completely fused with the shaft, but the medial epicondyle was still not united and is now missing. In the right radius both the upper and lower epiphyses are still open. The preserved lower epiphysis of the fragment of right femur is also not fused with the shaft. In the right tibia both the upper and lower epiphyses are still open, the same also being true for the available lower epiphysis of the left tibia.

The condition of the epiphyses indicates that this individual is at the most 17—18 years of age. Thus it is seen that we are not here dealing with a delayed eruption of the wisdom teeth as often

<sup>18</sup> Şenyürek: op. cit., 1941, pp. 222, 232, 240, and 250.

<sup>19</sup> Kansu, Ş. A. and Tunakan, S.: Türk Tarih Kurumu Alaca - Höyük kazılarında (1936—1944) Bakırçağı yerleşme katlarından çıkarılan iskeletlerin antropolojik incelenmesi. Belleten, vol. IX, No. 36, 1945, pp. 411—422.

<sup>20</sup> For the drawings of Alaca Höyük skull No. 9, see Kansu and Tunakan, 1945, Pls. LXXXIV and LXXXV.

<sup>21</sup> Şenyürek: op. cit., 1941.

<sup>22</sup> Ibid., 1941, Table III. See the column of two females under the heading of Alaca Höyük in this table.

<sup>23</sup> Kansu, and Tunakan: op. cit., 1945. Table 1.

<sup>24</sup> Şenyürek: op. cit., 1941. Table III.



occurs in the modern Europeans. The morphological features of this skull show that it belongs to a female individual.

*The Condition of the Sutures :*

In this calva the preserved part of pars verticis, pars obelica and pars postica of the sagittal suture are completely closed both endocranially and ectocranially<sup>25</sup>. While part of the lamdoid suture<sup>26</sup> at first appeared erased on the inner side, upon a closer examination, by disengaging the glued fragments it was determined that this suture is fully open on both the external and internal surfaces. The preserved parts of the coronal suture are still open both endocranially and ectocranially. Similarly, the squamous, parietomastoid, and the occipitomastoid sutures are still fully patent on the endocranial and ectocranial aspects of the skull.

Thus we see that in this calva also the sagittal suture has been prematurely closed, about 17—18 years before the usual time of complete closure of this suture, on the endocranial aspect of the skull.

*Other Features of the Skull :*

This calva which is rather short and very narrow, is dolichocephalic, orthocephalic and metriocranic (Table 8). The frontoparietal index, expressing the minimum frontal diameter as a percentage of the maximum skull width, is eurymetopic. This is due to the smallness of the skull breadth rather than the broadness of the forehead which is only moderately wide. The mean thickness of the parietal bone, measured about one centimeter above the squamous suture, is somewhat above the average.

The form of the skull is ovoid. The forehead is of moderate height and of medium slope. The brow ridges and glabella show a submedium development. The metopic suture is completely synostosed. The frontal eminences are of moderate development, while the parietal eminences are of medium size. There is no sagittal elevation in the frontal and parietal regions. Theus pramastoid crest,

<sup>25</sup> While this is also seen in the drawing published by Kansu and Tunakan, these authors have not noted the premature synostosis of this suture in their text. See Kansu, and Tunakan : op. cit., 1945, Pl. LXXXV.

<sup>26</sup> Şenyürek : op. cit., 1947, p. 56.

the mastoid process and the muscle markings on the calva show only a submedium development. The occiput is well-curved and protuberant. There is only a slight lambdoid flattening, but no plano-occipital flattening. There is no torus occipitalis.

As for the face, the nasal width is 22.5 mm., which is near some of the averages of modern Europeans given by Martin<sup>27</sup>. The canine fossa is of moderate depth. In the preserved right mandibular fragment, including also a part of the symphysis region, the mean angle of the mandible is near the average of Europeans given by Martin<sup>28</sup>, being only two degrees less (See Fig. 4). The chin shows only a moderate projection. The spina mentalis is of medium size. There is no mandibular torus. The mental foramen is single and is located below the interalveolar septum between the first and second premolars. The gonial angle is slightly everted.

In the maxilla the following teeth have been preserved : central and lateral incisors of the left side, the right canine, left and right first premolar, right second premolar, left and right first and second molars. The right central incisor is broken, while the left canine, right first premolar and the left second premolar have fallen off after death. In the right side of the mandible, the preserved teeth are : central incisor, first and second premolars, and first and second molars. The lateral incisor is broken and the canine has fallen off after death. In addition the following isolated teeth from the left side of the mandible are available : lateral incisor, first and second molars and the still unerupted third molar.

The measurements of the teeth are shown in Tables 11 and 12. The upper central incisor shows a slight, and the upper lateral incisor a moderate, degree of shovel-shape as described by Hrdlicka<sup>29</sup>. The lateral upper incisor of the right side is congenitally missing. In the first upper molar of both sides, there are four cusps. The hypocone is well-formed. On the other hand, in the second upper molar of both the right and left sides the hypocone is reduced in size. There is no Carabelli pit or Carabelli cusp in either one of the upper molars.

<sup>27</sup> Martin, R. : *Lehrbuch der Anthropologie* Jena, 1928, vol. II, p. 938.

<sup>28</sup> *Ibid.*, p. 984.

<sup>29</sup> Hrdlicka, A. : Shovel-shaped teeth. *American Journal of Physical Anthropology*, vol. 3, 1920.

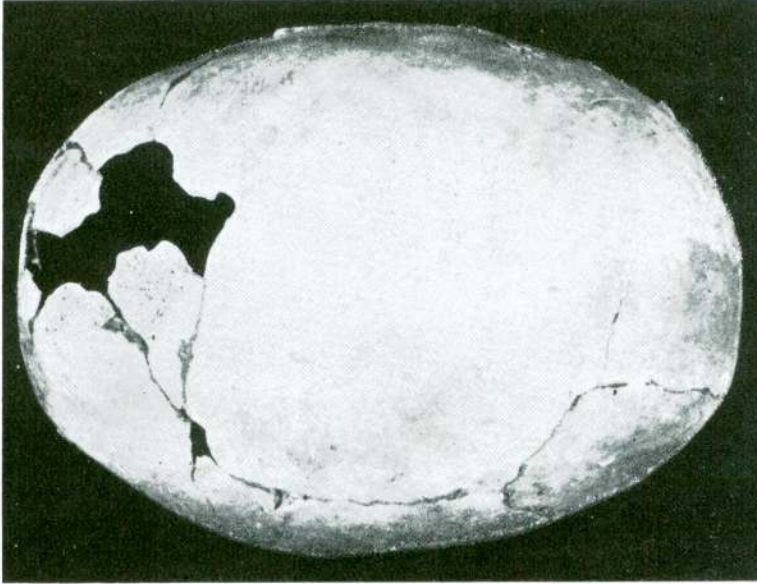


Fig. 1 — Kaledoruğu No. 1 : The skull in norma verticalis.

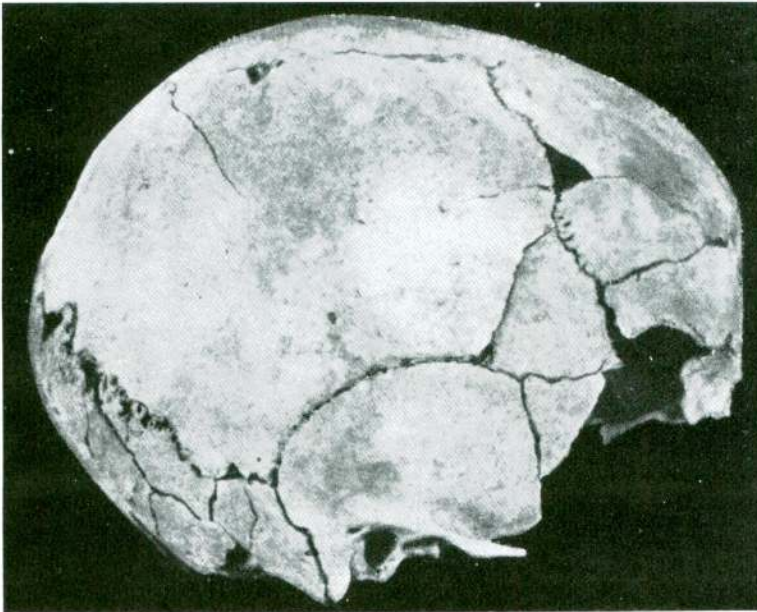


Fig. 2 — Kaledoruğu No. 1 : The Skull in norma lateralis.

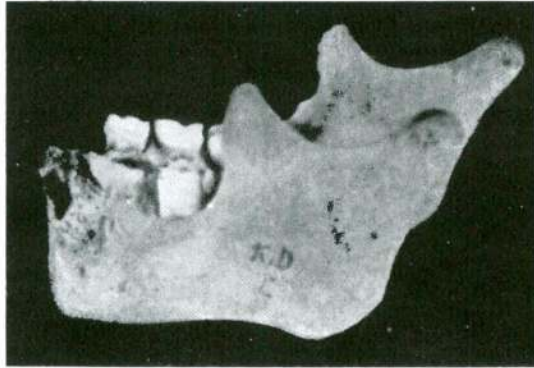


Fig. 3 — Kaledoruğu No. 1 : The mandible in norma lateralis.

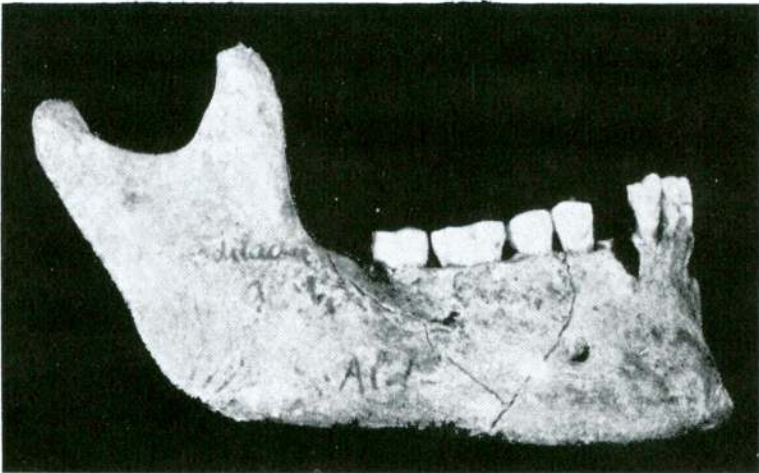


Fig. 4 — Alaca-Höyük No. 9 : The mandible in norma lateralis.

The lower incisors are not shovel-shaped. The second lower premolar has been slightly rotated about its axis. The first lower molar has five cusps on both sides. The mesoconid (hypoconulid) of this tooth is well-developed. The first lower molar shows the *Dryopithecus* pattern. In the left second lower molar there are also five cusps, but the mesoconid is reduced in size. On the other hand, in the right second lower molar there are only four cusps, the mesoconid being altogether lost. Both the right and left second lower molars show Milo Hellman's plus-pattern<sup>30</sup>. The left lower third molar possesses four main cusps and a small mesoconid. This tooth also shows the plus-pattern. The chewing surface of the crown of the third lower molar is coarsely wrinkled. In the mesio-buccal corner of the protoconid of this tooth a small dimple is observed. The bite of this individual, as is judged from the attrition of the incisors, was of the over-bite type.

The teeth, on the whole, are slightly worn. In the first upper and lower molars only some islands of dentine are exposed, while in the second upper and lower molar only the enamel is abraded and no dentine is exposed. There are no caries in any of the available teeth. Also there is no sign of pyorrhea.

The postcranial bones are all broken. The tibia is eurycnemic (index cnemicus=78.68)<sup>31</sup>.

The sum total of its characters shows that this skull represents an individual of the Mediterranean racial type.

### CONCLUSION

The two skulls studied in this report (Kaledoruğu No. I and Alaca Höyük No. 9) agree, from the viewpoint of morphological type, with the majority of Chalcolithic and Copper Age inhabitants of Anatolia, who were also longheaded, the brachycephals being rare in these periods<sup>32</sup>. These two skulls differ from the longheaded Chalcolithic and Copper Age inhabitants of Anatolia, mainly in that some of their sutures have synostosed prematurely. Of these, Kaledoruğu skull No. I shows a tendency in the direction of microcephaly.

<sup>30</sup> Hellman : op. cit., 1928.

<sup>31</sup> The sagittal and lateral measurements, at the level of foramen nutricium, of the right tibia are respectively 30.50 and 24.00 mm.

<sup>32</sup> See Şenyürek : 1941, 1949, 1950 and 1951.

TABLE 2  
Measurements of Kaledoruğu No. 1 : The Calva

Glabello-occipital length	153.50
Maximum width	112.00
Porion-bregma height	107.00? (right)
Mean thickness of parietal	2.30 (right)
Cranial index	72.96
Po-b-length index	69.70?
Po-b-breadth index	95.53?

TABLE 3  
Measurements of Kaledoruğu No. 1 : The Mandible

Condylo-symphyseal length	73.00
Bicondylar width	86.00?
Bigonial width	75.00
Height of ascending ramus (From gonion to the highest point of the condyle) <sup>1</sup>	35.00
Height of ascending ramus (projected)	32.00
Minimum breadth of ascending ramus	28.50
Height of corpus (At foramen mentale)	21.00 (right)
Thickness of corpus (At foramen mentale)	10.50 (right)
Bimental width (Distance between the two foramina mentalia)	34.00
Symphysis length	26.00
Mean angle mandible	127°
Mandibular index	84.88
Breadth index	87.20
Index of ascending ramus	81.42
Height-thickness index of the corpus	50.00

1 - Gonion is determined according to Jankowsky's method (See Jankowsky, W. : Über unterkiefermasse und ihren rassendiagnostischen Wert. Zeitschrift für Morphologie und Anthropologie. Band XXVIII, Heft 3, 1930, pp. 347—359).

TABLE 4  
Measurements of Kaledoruğu No. 1 : The Milk Teeth.

Maxillary Teeth	Length	Breadth	Robustness Value (1)	Crown Index (2)
First milk molar	6.3	8.1	51.03	128.56
Second milk molar	7.6	8.9	67.64	117.10

$$1 = \text{Length} \times \text{Breadth}$$

$$2 = \frac{\text{Breadth} \times 100}{\text{Length}}$$

TABLE 5  
Measurements of Kaledoruğu No. 1 : The Milk Teeth.

Mandibular Teeth (1)	Length	Breadth	Trigonid Breadth	Talonid Breadth	Robustness Value	Crown Index	Trigonid-Talonid Index (2)
Second milk molar	8.8?	7.8	7.6	7.8	68.64	88.63	102.63

1. As the first right lower milk molar is damaged its measurements have not been taken.

$$2 = \frac{\text{Talonid breadth} \times 100}{\text{Trigonid breadth}}$$

TABLE 6  
Measurements of Kaledoruğu No. 1 : The Permanent Teeth.

Maxillary Teeth	Length	Breadth	Height (Crown)	Robustness Value	Crown Index
M <sup>1</sup>	9.0	10.3	6.0	92.70	114.44

TABLE 7  
Measurements of Kaledoruğu No. 1 : The Permanent Teeth.

Mandibular Teeth	Length	Breadth	Trigonid Breadth	Talonid Breadth	Height (Crown)	Robustness Value	Crown Index	Trigonid- Talonid Index
M <sub>1</sub>	9.7	9.1	9.1	9.0	6.3+	88.27	93.81	98.90

TABLE 8  
Measurements of Alaca Höyük No. 9 : The Calva.

Glabello-occipital length	172.00
Maximum width	127.00?
Porion-bregma height	103.00
Minimum frontal diameter	95.00
Mean thickness of parietal	5.50
Nasal width	22.50
Cranial index	73.83
Po-b-length index	59.88
Po-b-breadth index	81.10
Fronto-parietal index	74.80



TABLE 9

Measurements of Alaca Höyük No. 9 : The Maxilla.

Palate-external length	48.00 *
Palate-external width	62.00 *
External palatal index	129.16

TABLE 10

Measurements of Alaca Höyük No. 9 : The Mandible.

Height of ascending ramus (From gonion to the highest point of the condyle)	51.00
Height of ascending ramus (projected)	44.00
Minimum breadth of ascending ramus	30.00 *
Height of corpus (At foramen mentale)	30.00 *
Thickness of corpus (At foramen mentale)	13.00 *
Symphysis length	33.50
Mean angle mandible	126°
Index of ascending ramus	58.52
Height-thickness index of the corpus	43.33 *

\* Measurements shown with an asterisk are the same as those of Kansu and Tunakan, op. cit. 1945.

TABLE 11

Measurements of Alaca Höyük No. 9 : The Permanent Teeth.

Maxillary Teeth	Length	Breadth	Height (Crown)	Robustness Value	Crown Index
I <sup>1</sup>	8.6	7.5	—	64.50	87.20
I <sup>2</sup>	7.2	6.5	—	46.80	90.27
C <sup>1</sup>	7.3	8.0	—	58.40	109.58
P <sup>3</sup>	6.3	8.5	—	53.55	134.92
P <sup>4</sup>	6.1	8.2	—	50.02	134.42
M <sup>1</sup>	10.6	11.5	—	121.90	108.49
M <sup>2</sup>	9.9	11.1	7.0	109.89	112.12

TABLE 12

Measurements of Alaca Höyük No. 9 : The Permanent Teeth.

Mandibular Teeth	Length	Breadth	Trigonid Breadth	Talonid Breadth	Height (Crown)	Robustness Value	Crown Index	Trigonid- Talonid Index
I <sub>1</sub>	5.2	6.5	—	—	—	33.80	125.00	—
I <sub>2</sub>	5.8	6.5	—	—	—	37.70	112.06	—
P <sub>3</sub>	6.6	7.1	—	—	—	46.86	107.57	—
P <sub>4</sub>	7.0	8.2	—	—	—	57.40	117.14	—
M <sub>1</sub>	11.1	10.6	10.5	10.6	—	117.66	95.49	100.95
M <sub>2</sub>	10.6	9.5	9.5	9.5	6.7	100.70	89.62	100.00
M <sub>3</sub>	10.5	9.2	9.1	9.2	6.9	96.60	87.61	101.09